

# UNDERSTANDING VESTIBULAR-EVOKED MYOGENIC POTENTIALS (VEMPs)

Vestibular-evoked myogenic potential (VEMP) testing is based on the vestibulo-collic reflex (VCR), which occurs between the saccule otolith organ and the sternocleidomastoid muscle (SCM). Specifically, the response pathway is from the saccule to the lateral vestibular nucleus via the inferior vestibular portion of cranial nerve VIII. The pathway then extends to the lateral vestibulospinal tract. The reflex arc is completed with the innervation of the SCM by cranial nerve XI, the Accessory Nerve (Colebatch & Halmagyi, 1992). The benefit of measuring VEMPs is an ability to identify lesions of the saccule, inferior vestibular nerve, and descending vestibulospinal pathways including the lower brainstem.

Since the VEMP is actually a myogenic recording from the large SCM muscle, it is quite easy to produce a response with clear P13 and N23 components compared to some other evoked potentials (e.g., ~200  $\mu$ V amplitude for VEMP vs. <1  $\mu$ V amplitude for ABR). The test is most commonly performed with a click or tone-burst stimulus but has also been observed using a non-acoustic tapping technique.

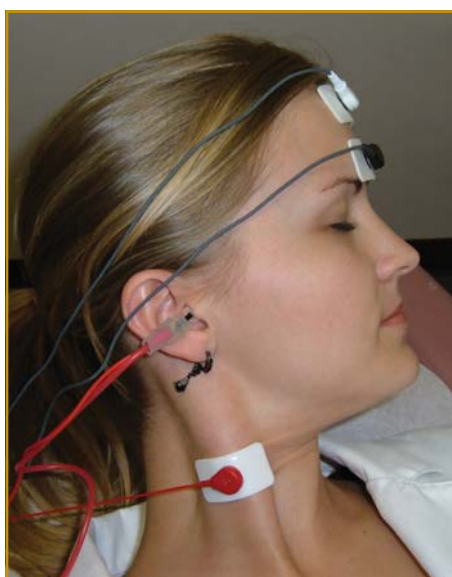Based on a unique ability to assess the vestibulo-collic reflex (VCR) pathway, the recording of VEMPs has provided useful diagnostic information on both otologic and neurologic conditions in patients ranging from otologic problems such as Meniere's disease, superior canal dehiscence syndrome (SCDS), and vestibular neuritis, to neurological disorders such as multiple sclerosis, spinocerebellar degeneration, and migraine. This sound-evoked potential appears robust to significant

responses may be absent, delayed in latency, reduced in amplitude, or elevated in amplitude. Liao and Young (2004) recently described results from VEMP studies in patients with migraine headaches and reported absent or delayed responses in many of the subjects. Following three months of medical intervention, normal VEMPs were obtained in 90% of the migraineurs.

Interestingly, intense stimulus levels of 95 – 100 dB nHL are typically needed to record VEMPs in the normal population, but for certain disorders reliable responses have been recorded at much lower levels. Brantberg et al. (1999) reports replicable VEMPs in patients with SCDS for stimulus levels as low as 70 – 75 dB nHL. We recently obtained clear and replicable responses down to 62 dB nHL, with stimulation to each ear, for a patient with bilateral SCDS subsequently confirmed with high resolution CT scan. Young et al. (2002) reported that augmented VEMPs may be obtained in patients with Meniere's disease as the fluid-distended saccule is in closer proximity to the stapes footplate. This is thought to increase the effective stimulus level reaching the saccule.

## PATIENT PREPARATION

The skin should be cleansed with alcohol, but abrading is not necessary. There is some variance among labs in terms of placement for the active (non-



Electrode montage and contraction of the right SCM sternocleidomastoid muscle.

Interpretation of VEMPs is based on latency or amplitude. As waveform labeling suggests, typical P13 absolute latency is 13 ms, while N23 is usually present at 23 ms. Many clinical vestibular laboratories advocate use of an 'asymmetry ratio' calculated as:

$$100 \frac{(\text{Amplitude}_{\text{Left}} - \text{Amplitude}_{\text{Right}})}{(\text{Amplitude}_{\text{Left}} + \text{Amplitude}_{\text{Right}})}$$

An amplitude asymmetry >30 – 47% is considered clinically significant.

sensorineural hearing loss; however, it is requisite that patients have a functioning middle ear system to elicit this response.

Depending on the disorder, P13-N23

inverting) and reference (inverting) electrodes. The positive and negative peaks and troughs will invert but the latency will be unaffected. Our preferred

VEMP Responses				
Pathology	Absent	Reduced	Enhanced	Delayed
<b>Otologic</b>				
Meniere's Disease	X	X	X	
Superior Canal Dehiscence Syndrome			X	
Neurolabyrinthitis	X	X		
Vestibular Neuritis	X	X		
<b>Neurologic</b>				
Migraine	X	X		X
Spinocerebellar Degeneration	X			X
Multiple Sclerosis	X			X
Brainstem Stroke	X			X

Instrumentation Parameter	Setting
Filter	High 1500 – 2000 Hz Low 20 – 30 Hz
Amplifier Gain Window	5,000 – 10,000 50 – 100 ms

Stimulus Parameter	Setting
Stimulus	Click Tone Burst (2 cycle Rise/Fall)
Presentation Level	95 – 100 dB nHL
Rate	5.1/s
Repetitions	128 (2-3 runs)

Factors That Influence VEMP Amplitude	
Factor	Optimal
Contraction of Sternocleidomastoid	~50_V
Stimulus Level	High Level (95 – 100 dB nHL)
Tone Burst Frequency	500 – 1000 Hz

electrode sites include the low forehead – ground, active (non-inverting) – point of SCM attachment at the collar bone and sternum *or* high forehead, and the reference (inverting) – on the belly of the SCM muscle. It is easier to use large electrodes, many of which come pre-gelled and are used for cardiac and myogenic recordings.

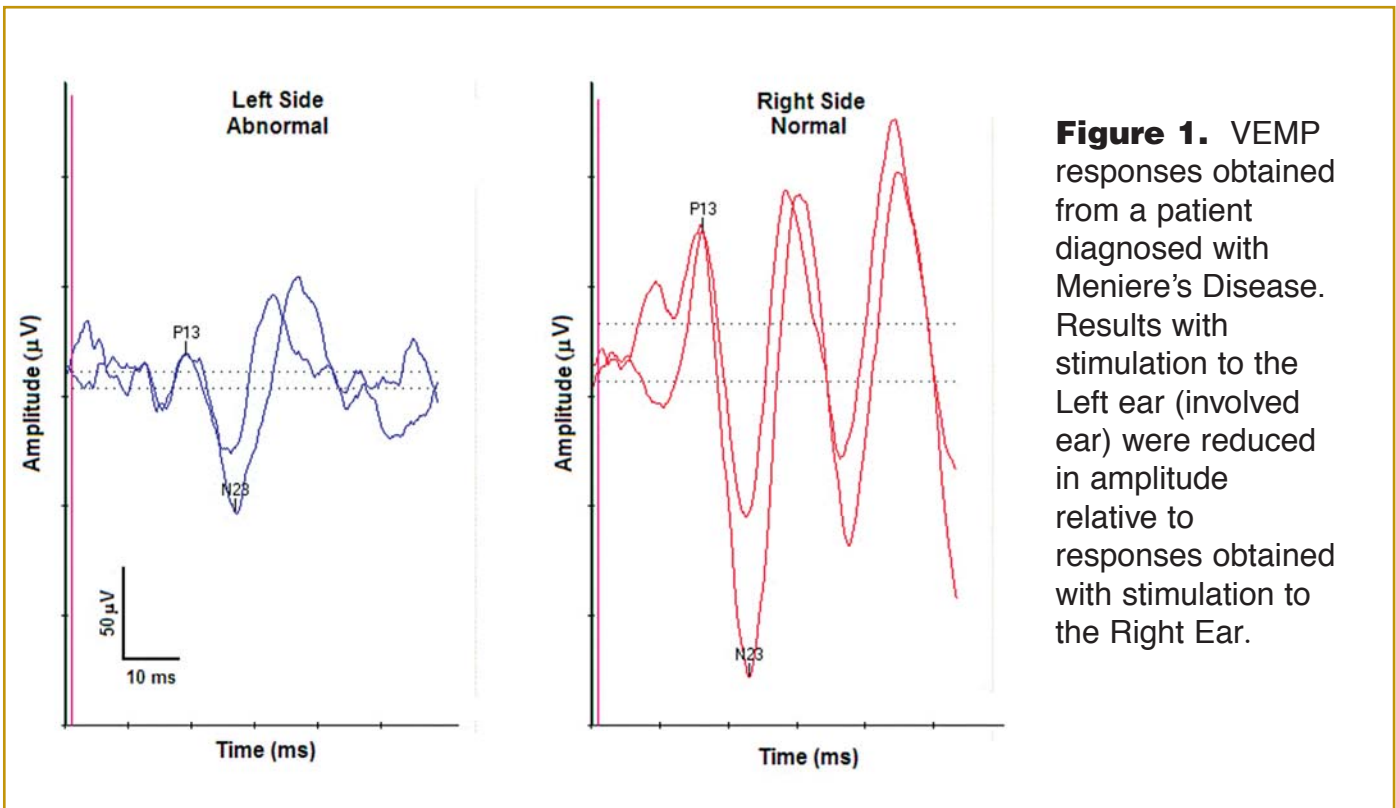
It is helpful to initially identify the SCM muscle and select appropriate electrode placement locations while lifting the head of the supine patient. The patient's head should be elevated several inches, and rotated to the right causing a clearly visible contraction of the SCM muscle. Once the electrodes have been placed on the right SCM, the

procedure is repeated for proper electrode placement with contraction of the left SCM.

With a one-channel ABR system, one side is tested and the electrodes need be changed in the preamplifier box to the other set of electrodes. We have found that it is easier to prep the patient and place the electrodes bilaterally even when using a one-channel system. When using a 2-channel system, you will record/test the ipsilateral side – channel 1, and monitor the contralateral SCM muscle activity on channel 2. Since there is no sound presented to the contralateral side, a VEMP should not be observed.

### PROTOCOLS

An evoked potential (EP) unit may be used with insert or traditional earphones to present the stimuli and record the SCM muscle response. No masking is necessary in the non-test (contralateral) ear. Fluorescent lights must be shut off to avoid electrical interference and the patient's eyes are closed during data collection. Background or ambient noise, however, is less of an issue with this large amplitude response compared with traditional ABR testing. It is imperative that there is an appropriate level of contraction of the patient's SCM muscle ipsilateral to the stimulus during the data collection period. Some authors advocate monitoring of SCM activation during recording to maintain a target level of ~50 microvolts when feasible. We have been able to record reliable VEMPs with the patient in the preferred supine position, with the head lifted and rotated away from the test ear. The test is conducted ipsilaterally with the acoustic stimulus delivered to the right ear when recording contraction of the right SCM muscle.



**Figure 1.** VEMP responses obtained from a patient diagnosed with Meniere's Disease. Results with stimulation to the Left ear (involved ear) were reduced in amplitude relative to responses obtained with stimulation to the Right Ear.


This requires the patient to turn their head to the *left* to cause the proper *right* SCM contraction.

### CODING AND REIMBURSEMENT ISSUES

Although there is no specific CPT code for VEMP testing, CPT 92585 is most likely applicable. According to the description of 92585 from the AMA CPT Manual (2004), this code is used for “auditory evoked potentials for evoked response audiometry and/or testing of the central nervous system; comprehensive”. The code 92586 is for limited testing. “Comprehensive” suggests bilateral testing and limited unilateral testing.

### SUMMARY

The VEMP provides diagnostic information that is otherwise unavailable regarding the saccule, inferior vestibular nerve, and VCR pathway. VEMPs are

useful for a wide range of clinical application. The test is fast, non-invasive and may significantly affect medical and non-medical management triage. There is an abundance of scientific articles and papers discussing VEMPs mostly in audiology, otolaryngology and neurology journals. Key references are provided below for additional information about this procedure. 

### REFERENCES AND SUGGESTED READINGS

Akin, F. & Murnane, O. (2001). Vestibular evoked myogenic potentials: Preliminary report. *J Am Acad Audiol*, 12: 445-452.  
 Brantberg, K., Bergenius, J., & Tribukait, A. (1999). Vestibular-evoked myogenic potentials in patients with dehiscence of the superior semicircular canal. *Acta Otolaryngol (Stockh)*, 119: 633-640.  
 Chen, C. & Young, Y. (2003). Vestibular evoked myogenic potentials in brainstem stroke. *Laryngoscope*, 113: 990-993.  
 Colebatch, J. & Halmagyi, G. (1992). Vestibular evoked potentials in human neck muscles before and after unilateral vestibular

deafferentation. *Neurology*, 42: 1635-1636.  
 Liao, L., & Young, Y. (2004). Vestibular evoked myogenic potentials in basilar artery migraine. *Laryngoscope*, 114: 1305-1309.  
 Ochi, K., Ohashi, T., & Watanabe, S. (2003). Vestibular-evoked myogenic potential in patients with unilateral vestibular neuritis: abnormal VEMP and its recovery. *J Laryngol Otol*, 117: 104-108.  
 Seo, T., Node, M., Yukimasa, A., & Sakagami, M. (2003). Furosemide loading vestibular evoked myogenic potential for unilateral Meniere's disease. *Otol Neurotol*, 24:283-288.  
 Takegoshi, H. & Murofushi, T. (2000). Vestibular evoked myogenic potentials in patients with spinocerebellar degeneration. *Acta Otolaryngol*, 120: 821-824.  
 Tsutsumi, T. et al. (2000). Prediction of the nerves of origin of vestibular schwannomas with vestibular evoked myogenic potentials. *Am J Otol*, 21(5): 712-715.  
 Versino, M. et al. (2002). Vestibular evoked myogenic potentials in multiple sclerosis patients. *Clin Neurophysiol*, 113(9): 1464-1469.  
 Young, Y., Wu, C. & Wu, C. (2002). Augmentation of vestibular evoked myogenic potentials: An indication for distended saccular hydrops. *Laryngoscope*, 112: 509-512.  
 Zapala, D., & Brey, R. (2004). Clinical experience with the vestibular evoked myogenic potential. *J Am Acad Audiol*, 15: 198-215.